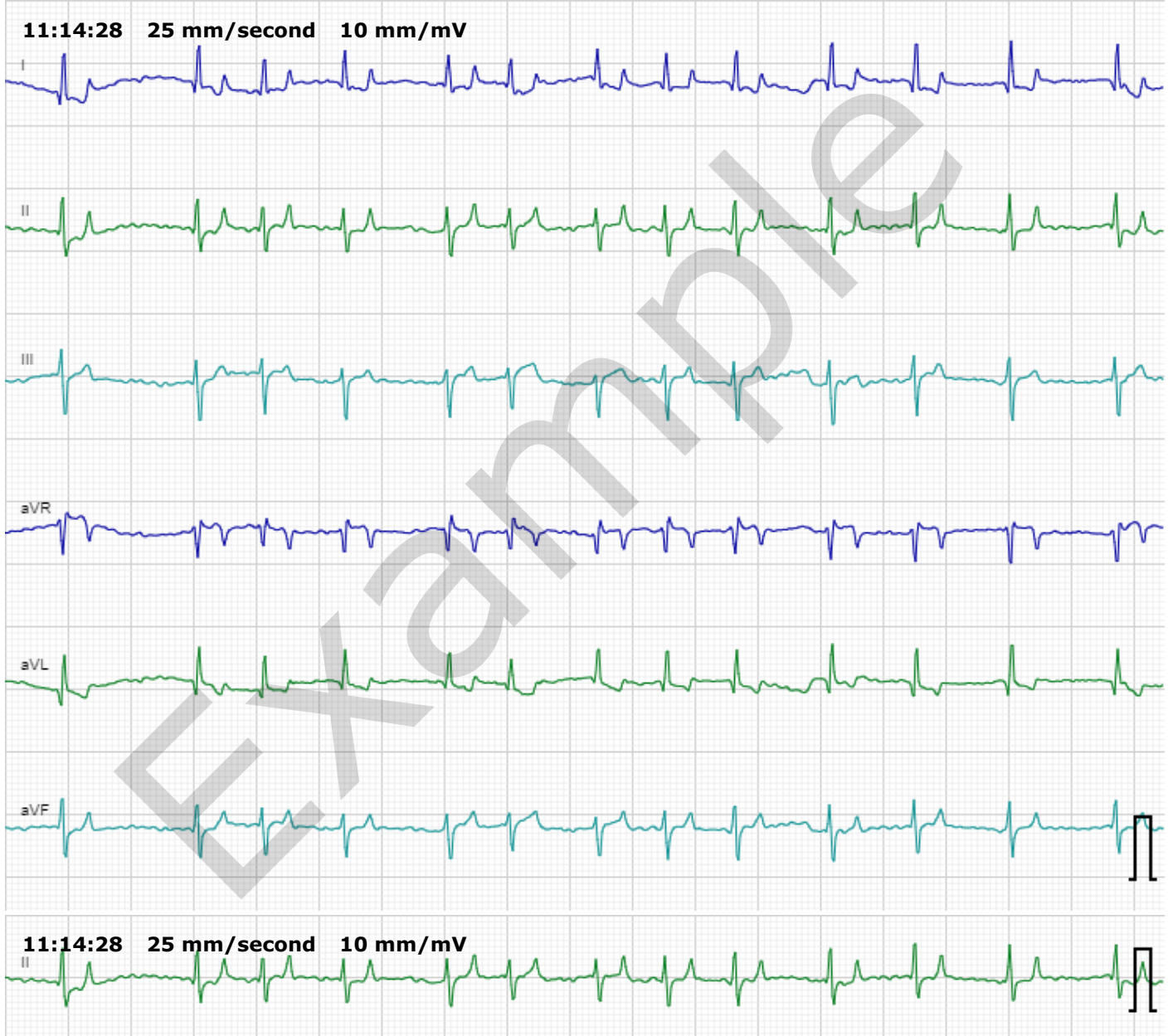


Dr. Demo Doctor

Type: Rest ECG **Date:** 11/09/2019 15:01:32 **Duration:** 00:01:03

Patient name:	Demo Patient	Weight:	58.0 kg	Species:	Dog
ID:	7267	History:	Atrial fibrillation HR 148	Breed:	
Email:		Medications:		Owner:	
Phone Number:		Code-procedure:		Spayed/Neutered:	No
Gender:	M				
Age:	5				



Signature: _____

Report / Conclusion:

A detailed analysis of 6 different leads was performed. Heart rate and rhythm, measurable intervals and amplitudes, and deflection morphology were all examined and revealed the following data:

HR=100-120/min
P=not applicable (NA)
PR=NA
QRS=60ms
R=0.5mv
QT=220

The heart rhythm is irregularly irregular with no evidence of P-waves.

Findings: Atrial fibrillation with a well controlled ventricular response rate is documented.

Conclusions and recommendations: the reported mild azotemia may be pre-renal (due to a chronically reduced cardiac output) and needs to be followed. If no clinical signs are present such as weakness, pallor, exercise intolerance or (typically right-sided) congestive heart failure (hepatomegaly, jugular venous distention, ascites and chronic, progressive muscle mass loss), no further pharmacotherapy is recommended at this time, but since things can, and are also likely to deteriorate, frequent enough monitoring for all of the above is highly advised.

Although amiodacore is underdosed for this dog's body weight, since heart rate is currently so well controlled, I would not increase the dose. However, there is a risk of white blood cell and liver toxicity even at low doses, which is to be taken into consideration and factored into the follow up plan.

In addition, hypothyroidism should be ruled out both as a possible reason for the surprisingly normal (slower than expected) ventricular response rate, AND as amiodacore (which contains iodine) can trigger either hypo- or hyperthyroidism in the more remote future.

Repeat the ECG along with a full bloodwork panel in up to 3 months from now, at the latest.

Lastly, if the owner is interested not only in rate control but also in rhythm control, consider a referral for cardioversion with a defibrillator-delivered direct-current electrical shock under general (but very short) anesthesia. If this is the owner's choice, the amiodacore dose needs to be temporarily increased to 800mg SID as of Day-Minus-14 prior to the scheduled procedure, and Ranolazin ("Ranexa") should be added at 1375mg (two tablets of 500 mg and one tablet of 375 mg) BID, from Day-Minus-2 until Day-Minus-1 prior to the procedure (a total of four doses altogether). Carlos needs to be fully fasted prior to the procedure and receive no medications at all at that same morning.

The owner should be advised that although cardioversion success rates are high, they are not 100%, and even if we do succeed, the achieved normal sinus rhythm may sometimes only last for a few days or weeks. However, because of the risks involved in chronic atrial fibrillation, if resources allow, this procedure is still recommended, as long as expectations remain realistic.

Dan Ohad, DVM, Ph.D. Diplomate ACVIM (Cardiology) Diplomate ECVIM-CA (Cardiology)

Sep 11, 2019

Signature: _____